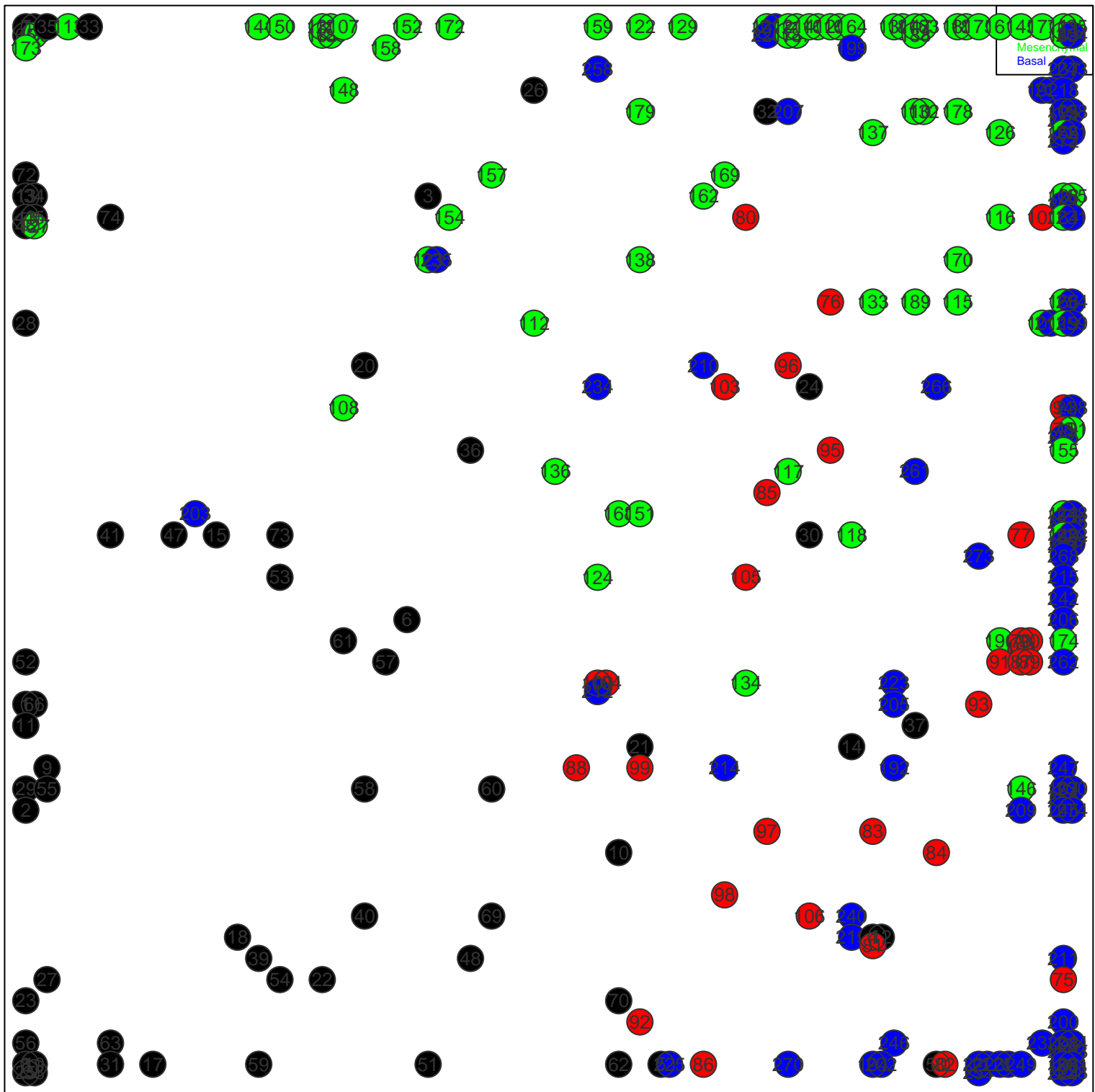
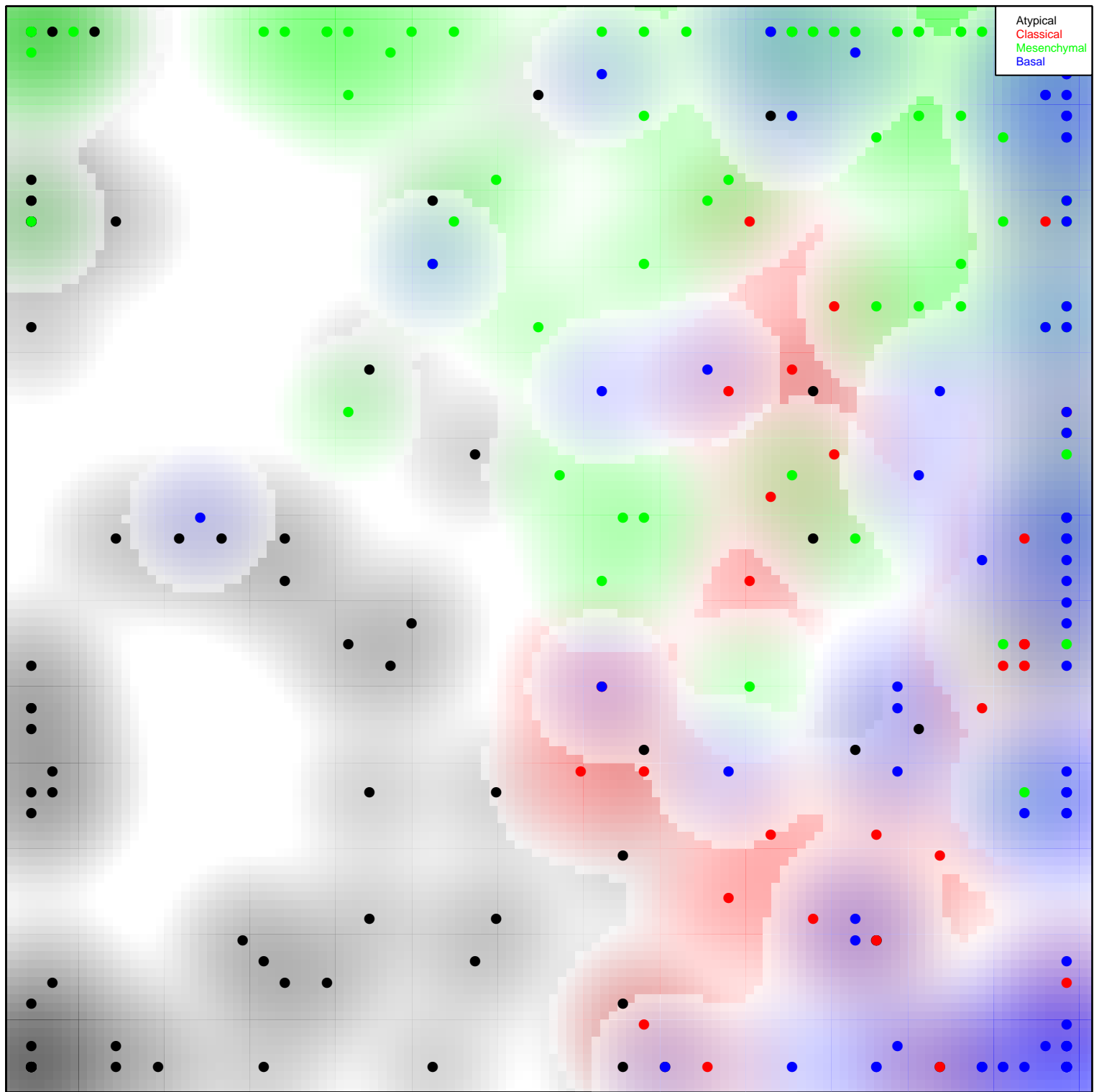




Atypical  
Classical  
Mesenchymal  
Basal





Atypical  
Classical  
Normal

